



# Acute Odontoid Fractures: Anterior Odontoid Fixation

Brian Perri, DO,\* Khawar Siddique, MD,\* Eli M. Baron, MD,\* and Carl Laurysen, MD†

Fractures of the dens are common injuries. The classification of these fractures remains controversial. Anterior odontoid fixation is a safe and effective means of stabilizing some of these injuries. We review classification of these injuries, treatment options, and surgical indications. Anterior odontoid fixation is reviewed in further detail, with an emphasis on surgical indications and a discussion of surgical technique.

Oper Tech Orthop 17:163-168 © 2007 Elsevier Inc. All rights reserved.

**KEYWORDS** odontoid fracture, anterior fixation, surgical indications

Fractures of the dens comprise 18% to 20% of cervical injuries, of which 65% to 74% are Anderson-D'Alonzo type II fractures.<sup>1,2</sup> The injury mechanism typically consists of ground-level falls in the elderly or high-velocity accidents in the younger population. The initial neurological injury rate is low. For example, among type II fractures in the elderly, the neurological injury rate is 3%.<sup>3</sup> However, the mortality rate in the older population is high, with a reported 33% in hospital mortality rate for those patients older than 65 years.<sup>3</sup> Hanigan and coworkers<sup>4</sup> published a review of 19 patients older than 80 years and found a similar mortality of 30% within 3 weeks of injury. Furthermore, cardiopulmonary complications are common in this patient population but vary depending on the type of treatment.<sup>3-5</sup>

An initial classification system for odontoid fractures was described in 1971.<sup>6</sup> This classification was modified in 1974 by the scheme of Anderson and D'Alonzo.<sup>7</sup> Although widely accepted and time-tested, the Anderson classification has been criticized for the ambiguity between type II and III fractures and for not addressing the complexity in multiple subtypes of type II fractures.<sup>8</sup>

Three types of odontoid fractures are described in the original Anderson system. Type I fractures, fractures through the tip of the dens, are rare (none were identified in a review by Hadley and coworkers of 229 C2 fractures<sup>9</sup>) and typically are considered clinically unimportant. Type II fractures are common but are also the most debated subgroup. These fractures

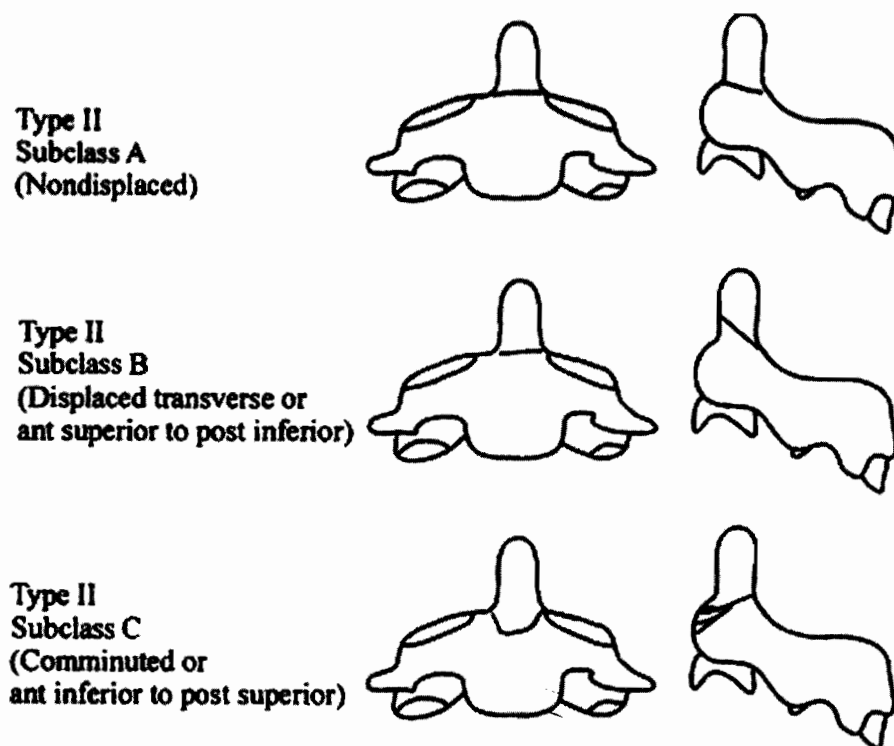
extend through the base of the dens whereas type III fractures extend into the C2 vertebral body. Clark and White<sup>1</sup>, in a Cervical Spine Research Society multicenter survey, agreed with the Anderson scheme but found the degree of angulation and amount of displacement to be important distinctions that were not addressed. Indeed, many contemporary surgeons argue that type II fractures are a heterogeneous group and should be divided into subgroups. These subtypes include the "shallow" type II fractures that partly involve the C2 body. One unique subtype proposed is called the type IIA fracture, which is defined by comminution across the fracture site.<sup>10</sup> This heterogeneous group of type II fractures was recognized by Grauer and coworkers, who proposed a modified classification scheme in 2005.<sup>8</sup> Additionally, this classification better delineates between type II and III fractures. Three subtypes of type II fractures are defined. Type III fractures are defined by the extension of the fracture line through the superior C2 facet. In addition, the authors noted a moderate reproducibility of this classification system (Fig. 1) by using retrospective review of 52 fractures.

Not only is the classification of odontoid fractures controversial, but also there are no standards or guidelines for the treatment of type II dens fractures. Instead, only retrospective reviews or case-control series exist from which treatments are recommended. This discrepancy has created difficulty in deciding even between operative versus nonoperative treatment. In general, treatment typically is based on fracture subtypes, I through III. The most controversial are the type II fractures. Proponents of conservative care espouse the non-invasive features of rigid or nonrigid cervical collars, whereas those in favor of surgical care point out the high fusion rates with instrumented fixation. Factors that affect surgical decision-making within the type II subtype include fracture line

\*Institute for Spinal Disorders, Cedars-Sinai Medical Center, Los Angeles, CA.

†Olympia Medical Center, Los Angeles, CA.

Address reprint requests to: Brian Perri, DO, Cedars-Sinai Medical Center, 444 S. San Vicente Blvd., Suite 800, Los Angeles, CA 90048. E-mail: perrib@cshs.org



**Figure 1** Grauer and coworkers<sup>8</sup> subdivision of type II odontoid fractures based on fracture morphology. Reprinted with permission from Grauer et al.<sup>8</sup>

angle (transverse and oblique orientation), amount of displacement, and degree of comminution.

## History of Anterior Odontoid Fracture Fixation

Nakanishi and coworkers began using this technique in 1978.<sup>11</sup> Since then, both single- and dual-screw techniques have been described. In 1999, Subach and coworkers<sup>12</sup> published a retrospective review of 26 patients (mean age, 35 years) with type II dens fractures treated with a single cortical lag screw and postoperative nonrigid bracing. The fusion rate was reported to be 96%, whereas the complication rate caused by surgical technical difficulties (for example, poor placement of screw) was 8%. Overall, fusion rates of 80% to 100% have been described with anterior screw fixation of both type II and “shallow” type III fractures.

Some surgeons have advocated a double-screw technique. A prospective review of 30 patients with type II fractures treated with two 2.7-mm self-tapping titanium screws showed a fusion rate of 100% and no major complications.<sup>13</sup> However, the authors did admit that the dual-screw technique is technically challenging. Others have published a fusion rate of 87% with both single- and dual-screw dens fixation.<sup>14</sup> Nevertheless, Sasso and coworkers noted anterior odontoid fixation with 1 or 2 screws to be biomechanically equivalent<sup>15</sup>; thus, the popularity of the 2-screw technique has waned.

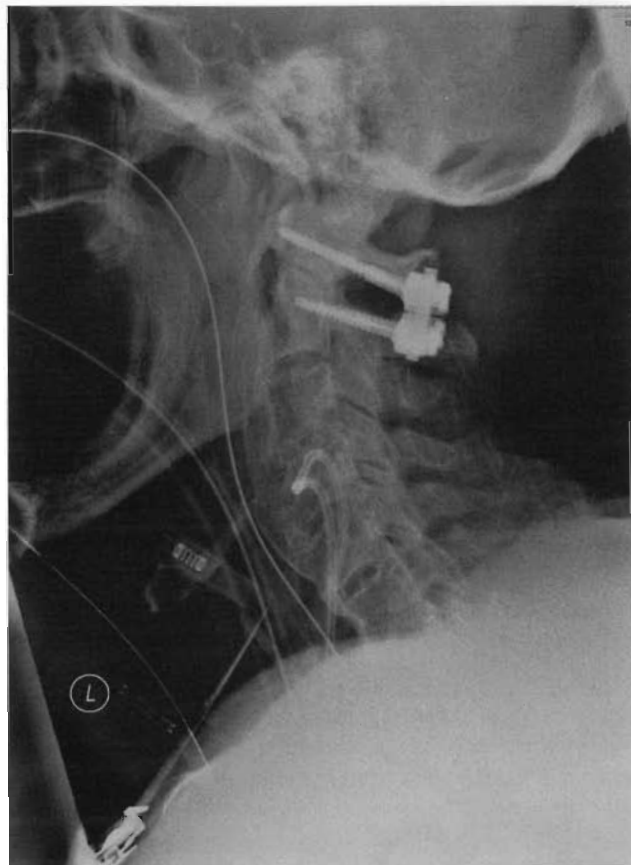Various modifications of the anterior technique have been described, including multiple variations of retractors<sup>16–18</sup> and

placement of screws using fluoroscopic-based navigation systems.<sup>19</sup> Additionally a cadaveric study using bioresorbable odontoid screws has been performed.<sup>20</sup> An endoscopic-assisted anterior screw fixation also has been described. However, that case resulted in pseudoarthrosis.<sup>21</sup> More recently, percutaneous odontoid screw fixation has been described.<sup>22</sup>

## Surgical Indications

Most authors agree that acute odontoid fractures with greater than 6 mm of displacement that cannot be reduced and stabilized in a halo or fractures associated with neurological deficit should be treated surgically. Historically, the common surgical treatment for type II fractures was posterior C1 to 2 fusion, including techniques such as Brooks, Gallie, and Sonntag fusions. More recently, C1 to C2 transarticular screws, and C1 lateral mass with C2 pars/pedicle screws have been advocated.<sup>12</sup> Fusion rates as great as 96% in type II fractures treated with posterior cervical fusion have been described (Fig. 2).<sup>1</sup> Nevertheless, posterior C1 to C2 fusion is associated with significant loss of neck motion. Typically, 50% of axial rotation and 10% of flexion-extension of the neck are lost with a C1–C2 arthrodesis.<sup>23</sup> As a result, posterior fusion is more commonly used in chronic rather than acute dens fractures. Additionally, patients with significant kyphotic deformities, osteoporosis (where anterior screw purchase is suspect), Grauer Type IIC (reverse obliquity fractures),<sup>8</sup> and those with significant comminution may warrant a posterior C1 to C2 fusion.

For the repair of a significant number of acute dens frac-



**Figure 2** Lateral film demonstrating type II odontoid fracture treated with C1 lateral mass screw, C2 pars-pedicle screw construct.

tures, anterior screw fixation has gained popularity. Grauer Type IIB (anterior superior to posterior fracture morphology) and displaced transverse fractures are type II fractures subtypes that typically are good indications for anterior screw fixation. The advantages of this procedure include the conferral of immediate stability without the need for an external orthosis in most cases, preservation of C1 to C2 motion, a high fusion rate, and a cost-effective surgical treatment. A single odontoid screw is less expensive than posterior atlantoaxial fusion alternatives and typically results in an earlier return to work and activity for the patient as compared with external immobilization or posterior fusion.<sup>24</sup>

## Surgical Technique

The Apfelbaum technique for anterior odontoid fixation has gained popularity and is described here. The patient is positioned with the neck neutral in the sagittal plane. With fluoroscopy in place, reduction of the fracture is attempted. Commonly, the fracture reduces with gentle traction and cervical extension. It is critical to evaluate for possible spinal canal compromise if the fracture does not reduce in extension or if there is a retrolisthesed bone fragment. The patient's cervical spine is gently returned to the neutral position until the spikes of the Apfelbaum guide are engaged into C3. With

the aid of the provided guide tube and gentle manipulation, the fracture can then be reduced under fluoroscopic control.

An incision is made along anterior skin crease at the level of C5 to C6 (Fig. 3). A Smith-Robertson or Cloward approach is performed to access the prevertebral space. The longus colli muscles are elevated bilaterally along the medial border to aid in retractor placement. Cloward-type retractor blades are inserted under the coli muscles bilaterally. Blunt dissection through the prevertebral fascial plane is performed using a Kittner dissector until the anterior-inferior C2 vertebral body is accessed and confirmed with lateral fluoroscopy. The Apfelbaum system uses a superior placed retractor blade to protective pharyngeal tissues. This retractor blade attaches to the modified Cloward retractor.

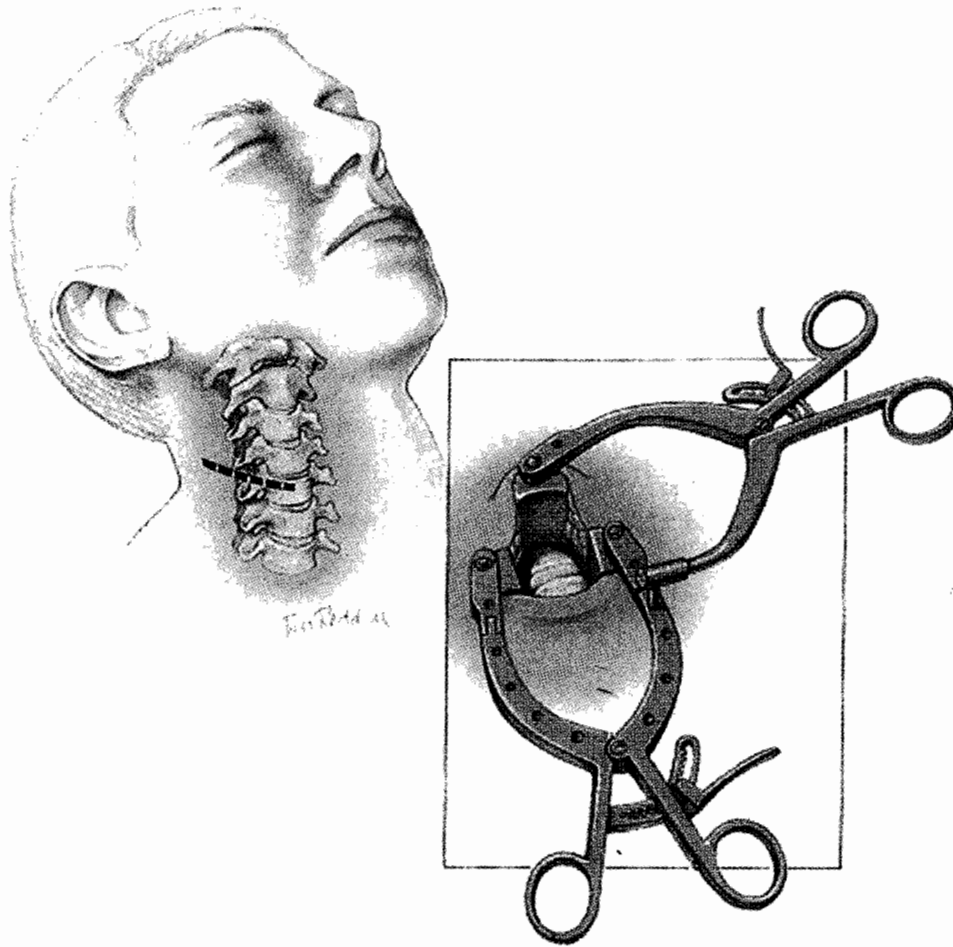
The entry site for the drill is the midline, anterior-inferior edge of C2. This entry site can be slightly recessed in the anterior-most aspect of the C2 to C3 disc space. This position is confirmed on AP and lateral fluoroscopy. A 2-mm K-wire is impacted 3 to 5 mm into the desired entry site. A 7-mm hollow core hand drill is passed over the K-wire. A groove is then drilled into the anterior face of C3 and the annulus of C2 to C3 to accommodate the drill guide. A spiked outer drill guide tube is placed over the wire. This guide is used to maintain alignment during drilling, tapping, and placing of the odontoid screw. As mentioned previously, the guide also may assist in the fracture reduction and to align C2 to C3 with the odontoid C1-complex

A pilot hole is drilled through the body of C2 and into the fracture fragment using a calibrated drill bit. The apical cortex of the odontoid is penetrated (Fig. 4). A tap is inserted into the drill guide and used to tap the pilot hole up to the apical cortex. A cortical titanium lag screw is inserted into the guide tube and advanced through the tapped hole. The head of the screw is then recessed into the C2 body (Figs. 5 and 6).<sup>24</sup>

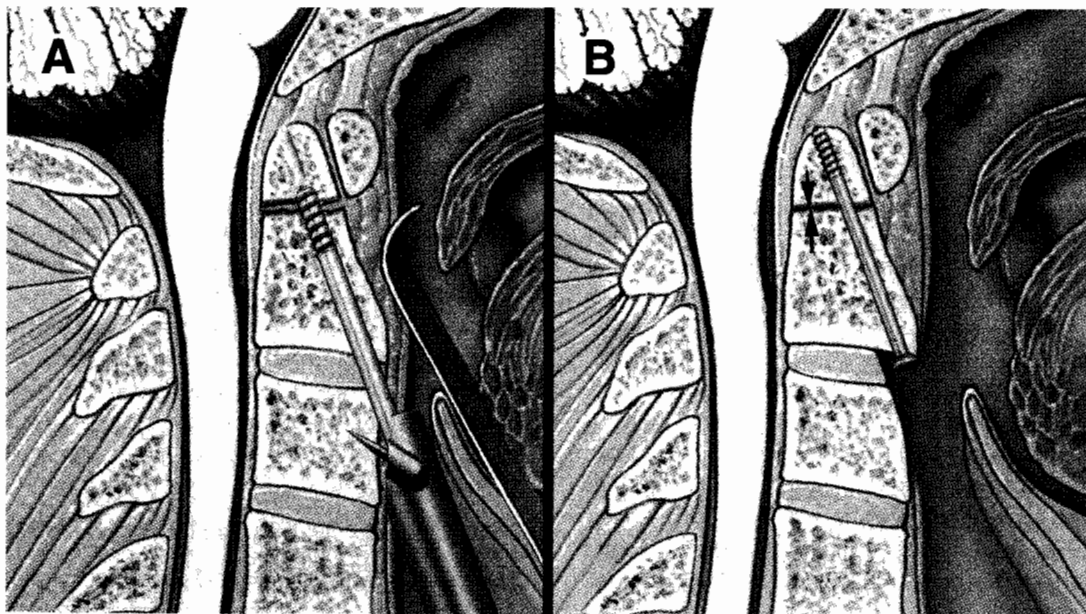
Alternatively, other fracture fixation methods have been described using an anterior cervical approach. The fracture reduction is performed in the same manner described previously. After obtaining adequate surgical exposure to the anterior-inferior C2 vertebral body, a threaded K-wire is drilled across the fracture and docked into the cortical bone of the proximal odontoid fragment. Again, biplanar fluoroscopy is used, which is critical to verify a "center-center position" for the K-wire in both planes if a single screw technique is used. The K-wire should be in the bone on all images, ensuring several millimeters for the final screw diameter. The K-wire should be at the tip of the odontoid. Appropriate fracture reduction should be verified after placement of the K-wire. The K-wire can then be gently tapped through the cortex using a small mallet. Either a cannulated screw technique or lag-screw technique can be used for final screw purchase.

## Postoperative Management

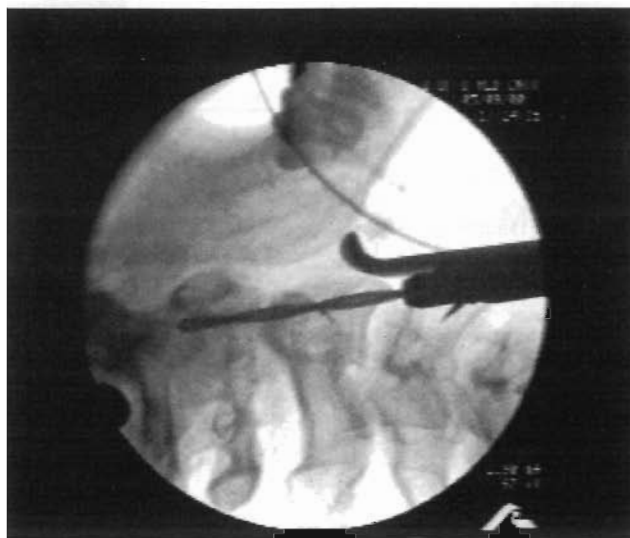The most appropriate type of postoperative bracing is still debatable. We typically prefer a rigid collar such as Aspen or Philadelphia. Halo immobilization after fusion is typically unnecessary, unless fracture fixation is tenuous. Similarly, a



**Figure 3** A standard incision is made along the skin crease at C5 to C6. After the longus colli muscles are elevated bilaterally, an Apfelbaum retractor system is used to protect soft tissues. Reprinted with permission from Apfelbaum et al.<sup>27</sup>



**Figure 4** Apfelbaum drill guide docked on C3 with advancing drill bit. Reprinted with permission from Apfelbaum et al.<sup>27</sup>



**Figure 5** (A) A single lag screw is placed across the fracture through the Apfelbaum drill guide. (B) The result is compression across the fracture line. The head of screw is recessed into the C2 body.

Minerva or cervicothoracic brace typically is unnecessary after surgical fixation. Complications after the procedure have been reported ranging from 8% to 24%,<sup>12,25-30</sup> including dysphagia, cranial nerve injury, infection, vascular injury, tracheal, esophageal injury, neurologic injury, pseudarthrosis, instrumentation failure/malposition, and death. Additionally, controversy exists as to whether the procedure is associated with significantly more morbidity in elderly patients.<sup>26,29</sup> Nevertheless, anterior odontoid fixation remains an important treatment option with excellent results being reported in experienced hands.<sup>12,27</sup>

## Alternative Treatment Options

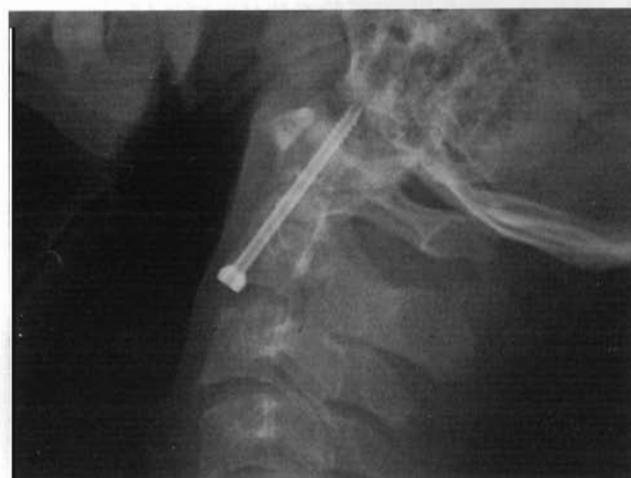Posterior C1–C2 fusion or longer posterior constructs remain the main alternative for the surgical treatment of odontoid fractures. Alternatively, the lateral approach of Barbour and Whitesides for anterior C1 to C2 arthrodesis may be used.<sup>31</sup>

Medical options consist of either rigid or nonrigid bracing. In this age of improved medical techniques, offering no treatment to a patient is rarely necessary. Even the type I relatively benign fractures are treated with a cervical collar. Bracing consists of either rigid (Halo vests) or nonrigid (eg, Aspen, Philadelphia collars) immobilizers. Halo vests are commonly prescribed with type II fractures but are associated with prolonged morbidity, especially in the elderly. A retrospective review of 38 patients with type II fractures treated with a halo vest compared with 40 treated surgically illustrated a significant increase in morbidity and mortality with the use of the halo vest (mortality rate of 42% compared with 20%; and major complication rate of 66% versus 36%).<sup>3</sup> Other less significant halo vest complications have been reported and include pin loosening, pin site infection, and pressure sores.<sup>32</sup> More importantly, the immobility as a result of the vest is significant but arguably difficult to measure. Tashjian and coworkers<sup>3</sup> observed a 26% incidence of cardiac arrest

with the use of halo vests compared with 5% of those treated without.

Type II and III fractures can be treated with a halo vest, but the success rate varies in the literature. In a retrospective review of 14 patients, fractures considered unstable (6 mm or more displacement) were reduced under x-ray and treated with a halo vest for 12 weeks. Fusion rate was 86%, but there was long-term pain with measurable fracture site motion (indicating probable pseudarthrosis) in 29%.<sup>33</sup> In another report, the nonunion rate of type II fractures treated with bracing or halo vest was 28% but varied according to amount of initial fracture displacement. In those patients with less than a 6-mm displacement compared with more than 6 mm, there was a pseudarthrosis rate of 10% versus 78%, respectively.<sup>9</sup> Additionally, Della Torre and coworkers compared halo-plaster immobilization with Minerva immobilization in 47 type II odontoid fractures.<sup>34</sup> They concluded halo-plaster immobilization to be a more effective method of immobilization. Additionally, they reported a higher nonunion risk in type II fractures that presented with posterior displacement. Overall, there is an approximate 70% fusion rate with halo immobilization for odontoid fractures.<sup>35</sup> Lennarson and coworkers<sup>16</sup> published a Class II case-control study of halo immobilization in type II fractures. They found a significant increase in pseudarthrosis in patients ages 50 years or older. Variables such as amount and direction of displacement did not affect the fusion rate. However, their data are confounded by a significant selection bias.

Stable type II and III fractures can be effectively treated with cervical (Philadelphia or Miami) collars. The results of this treatment, however, may be less than ideal. In a retrospective review of 26 patients with type II/III fractures with displacement less than 5 mm, flexion/extension movement less than 2 mm, no neurological deficit, and angulation less than 11° treated with a hard collar, the complication rate was 11% with a failure rate (operation required) of 8% whereas a pseudarthrosis rate of 26% (type II) and 14% (type III) was reported. The average patient age in that report was 59.1



**Figure 6** Final lateral radiograph demonstrating odontoid screw in position.

years, 61% of patients had persistent symptoms at follow-up, and 39% fused in malalignment.<sup>37</sup>

Critics of bracing note the relatively high rate of pseudarthrosis and fear the risk of progressive myelopathy or sudden neurological deterioration. Although instability caused by a dens fracture can cause progressive myelopathy, the risk is poorly defined. Crockard and coworkers<sup>2</sup> published a retrospective review of 16 patients, the majority with type II fractures with a delayed diagnosis, and thus presented with progressive myelopathy. They concluded that late myelopathy following odontoid fracture may be more common than previously believed. That population, however, was highly skewed as a result of referral bias. Therefore, an accurate incidence of delayed myelopathy from unrecognized odontoid fractures is difficult to determine.

## Conclusion

Anterior odontoid fixation is a safe technique, which has a high union rate in appropriately selected patients. The ultimate technique of fixation, whether via an anterior approach or a posterior cervical fusion, should be based on individual patient factors such as fracture morphology, medical comorbidities, and surgeon preference and experience.

## References

- Clark CR, White AA 3rd: Fractures of the dens. A multicenter study. *J Bone Joint Surg* 67:1340-1348, 1985
- Crockard HA, Heilman AE, Stevens JM: Progressive myelopathy secondary to odontoid fractures: Clinical, radiological, and surgical features. *J Neurosurg* 78:579-586, 1993
- Tashjian RZ, Majercik S, Biffl WL, et al: Halo-vest immobilization increases early morbidity and mortality in elderly odontoid fractures. *J Trauma* 60:199-203, 2006
- Hanigan WC, Powell FC, Elwood PW, et al: Odontoid fractures in elderly patients. *J Neurosurg* 78:32-35, 1993
- Muller EJ, Wick M, Russe O, et al: Management of odontoid fractures in the elderly. *Eur Spine J* 8:360-365, 1999
- Schatzker J, Rorabeck CH, Waddell JP: Fractures of the dens (odontoid process). An analysis of thirty-seven cases. *J Bone Joint Surgery* 53:392-405, 1971
- Anderson LD, D'Alonzo RT: Fractures of the odontoid process of the axis. *J Bone Joint Surg* 56:1663-1674, 1974
- Grauer JN, Shafi B, Hilibrand AS, et al: Proposal of a modified, treatment-oriented classification of odontoid fractures. *Spine J* 5:123-129, 2005
- Hadley MN, Dickman CA, Browner CM, et al: Acute axis fractures: A review of 229 cases. *J Neurosurg* 71:642-647, 1989
- Hadley MN, Browner CM, Liu SS, et al: New subtype of acute odontoid fractures (type IIA). *Neurosurgery* 22:67-71, 1988
- Nakanishi T, Sasaki T, Tokita N: Internal fixation for the odontoid fracture. *Orthop Trans* 6:176, 1982
- Subach BR, Morone MA, Haid RW Jr., et al: Management of acute odontoid fractures with single-screw anterior fixation. *Neurosurgery* 45:812-819; discussion 819-820, 1999
- ElSaghir H, Bohm H: Anderson type II fracture of the odontoid process: Results of anterior screw fixation. *J Spinal Disord* 13:527-530; discussion 531, 2000
- Fountas KN, Kapsalaki EZ, Karampelas I, et al: Results of long-term follow-up in patients undergoing anterior screw fixation for type II and rostral type III odontoid fractures. *Spine* 30:661-669, 2005
- Sasso R, Doherty BJ, Crawford MJ, et al: Biomechanics of odontoid fracture fixation. Comparison of the one- and two-screw technique. *Spine* 18:1950-1953, 1993
- Apfelbaum R: Anterior screw fixation of odontoid fractures, in Camins M, O'Leary P (eds): *Diseases of the Cervical Spine*. Baltimore, Williams & Wilkins, 1992, pp 603-608
- Hott JS, Henn JS, Sonntag VK: A new table-fixed retractor for anterior odontoid screw fixation: Technical note. *J Neurosurg* 98:294-296, 2003
- Shalayev SG, Mun IK, Mallek GS, et al: Retrospective analysis and modifications of retractor systems for anterior odontoid screw fixation. *Neurosurg Focus* 16:E14, 2004
- Battaglia TC, Tannoury T, Crowl AC, et al: A cadaveric study comparing standard fluoroscopy with fluoroscopy-based computer navigation for screw fixation of the odontoid. *J Surg Orthop Adv* 14:175-180, 2005
- Ames CP, Crawford NR, Chamberlain RH, et al: Biomechanical evaluation of a bioresorbable odontoid screw. *J Neurosurg* 2:182-187, 2005
- Hashizume H, Kawakami M, Kawai M, et al: A clinical case of endoscopically assisted anterior screw fixation for the type II odontoid fracture. *Spine* 28:E102-E105, 2003
- Chi YL, Wang XY, Xu HZ, et al: Management of odontoid fractures with percutaneous anterior odontoid screw fixation. *Eur Spine J* 2007 Mar 3; [Epub ahead of print]
- White AI III, Panjabi M: *Clinical Biomechanics of the Spine* (ed 2). Philadelphia, JB Lippincott, 1990
- Finn M, Fasset D, Apfelbaum R: Odontoid Screw Fixation, in Vaccaro AR, Baron EM (eds): *Operative Techniques: Spine Surgery*. Philadelphia, Elsevier, (in press)
- Aebi M, Etter C, Coscia M: Fractures of the odontoid process. Treatment with anterior screw fixation. *Spine* 14:1065-1070, 1989
- Andersson S, Rodrigues M, Olerud C: Odontoid fractures: High complication rate associated with anterior screw fixation in the elderly. *Eur Spine J* 9:56-59, 2000
- Apfelbaum RL, Lonser RR, Veres R, et al: Direct anterior screw fixation for recent and remote odontoid fractures. *J Neurosurg* 93:229-231, 2000
- Arand M, Lemke M, Kinzl L, et al: [Incidence of complications of the screw osteosynthesis of odontoid process fractures]. *Zentralbl Chir* 126:610-615, 2001
- Borm W, Kast E, Richter HP, et al: Anterior screw fixation in type II odontoid fractures: Is there a difference in outcome between age groups? *Neurosurgery* 52:1089-1092; discussion 1092-1084, 2003
- Lee SH, Sung JK: Anterior odontoid fixation using a 4.5-mm Herbert screw: The first report of 20 consecutive cases with odontoid fracture. *Surg Neurol* 66:361-366; discussion 366, 2006
- Vaccaro AR, Ring D, Lee RS, et al: Salvage anterior C1-C2 screw fixation and arthrodesis through the lateral approach in a patient with a symptomatic pseudoarthrosis. *Am J Orthop* 26:349-353, 1997
- Garfin SR, Botte MJ, Waters RL, et al: Complications in the use of the halo fixation device. *J Bone Joint Surg* 68:320-325, 1986
- Komadina R, Brilej D, Kosanovic M, et al: Halo jacket in odontoid fractures type II and III. *Arch Orthop Trauma Surg* 123:64-67, 2003
- Della Torre P, Fiacca C, Lignini S: An evaluation of the results of two non-surgical methods in the treatment of fractures of the odontoid process. *La Chirurgia Degli Organi di Movimento* 85:45-52, 2000
- Traynelis VC: Evidence-based management of type II odontoid fractures. *Clin Neurosurg* 44:41-49, 1997
- Lennarson PJ, Mostafavi H, Traynelis VC, et al: Management of type II dens fractures: A case-control study. *Spine* 25:1234-1237, 2000
- Muller EJ, Schwinnen I, Fischer K, et al: Non-rigid immobilisation of odontoid fractures. *Eur Spine J* 12:522-525, 2003